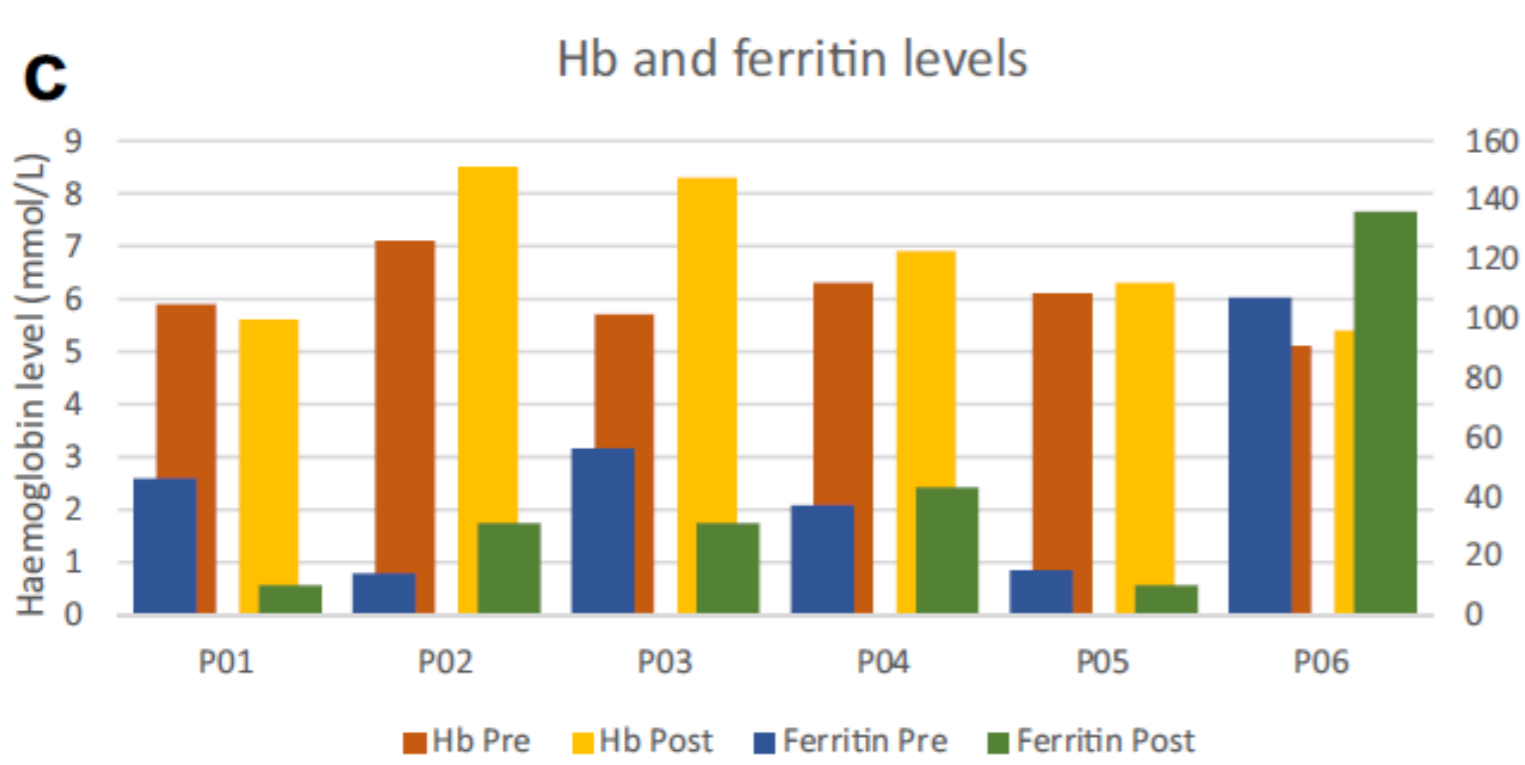
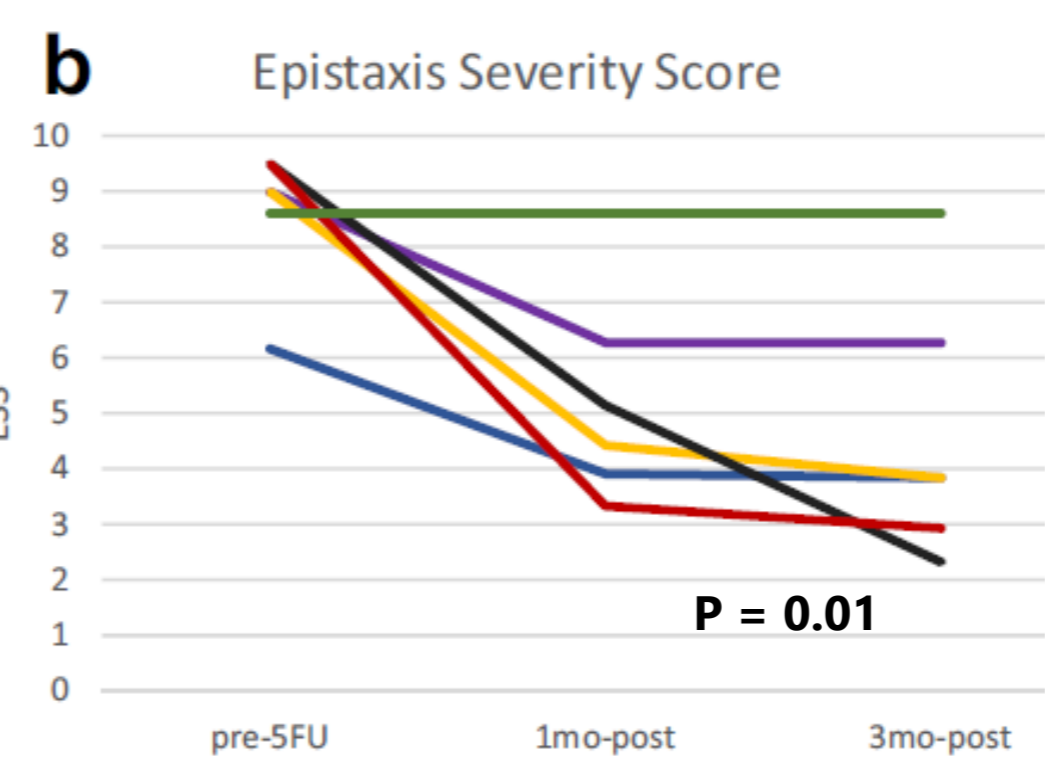
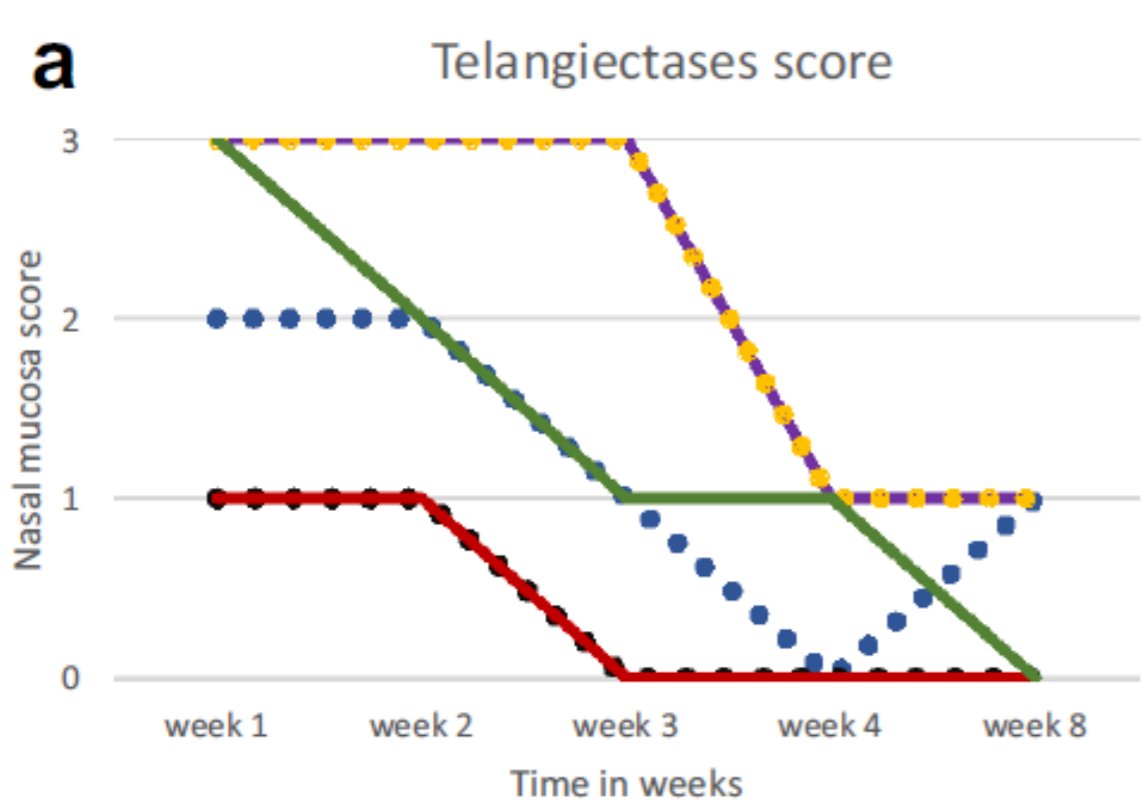
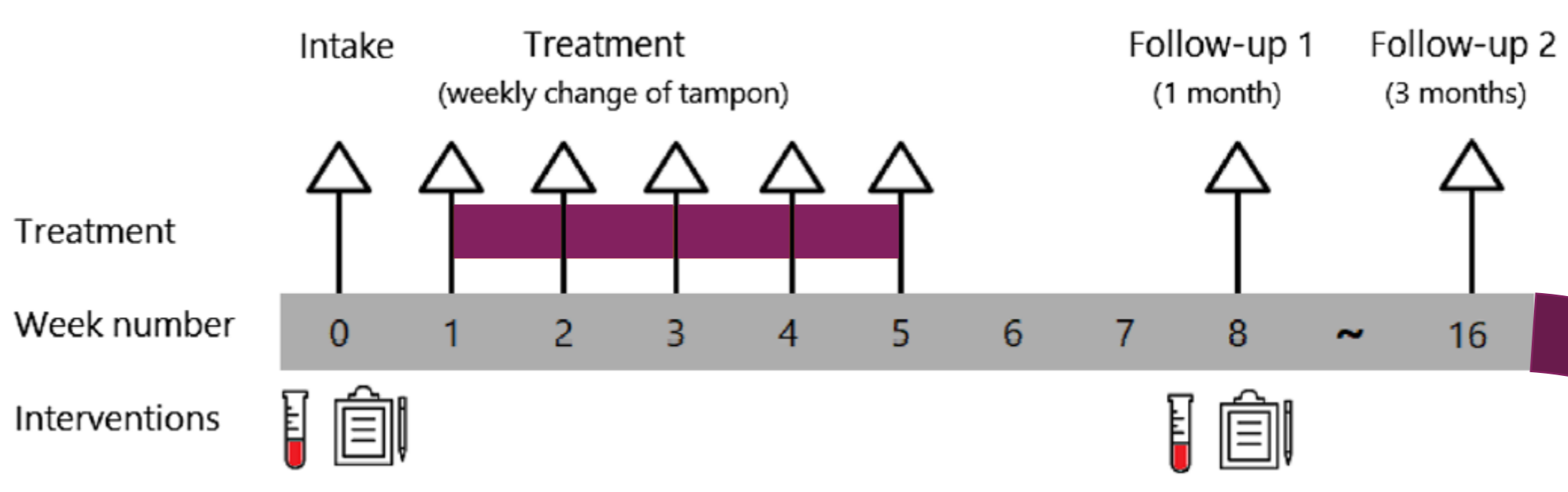
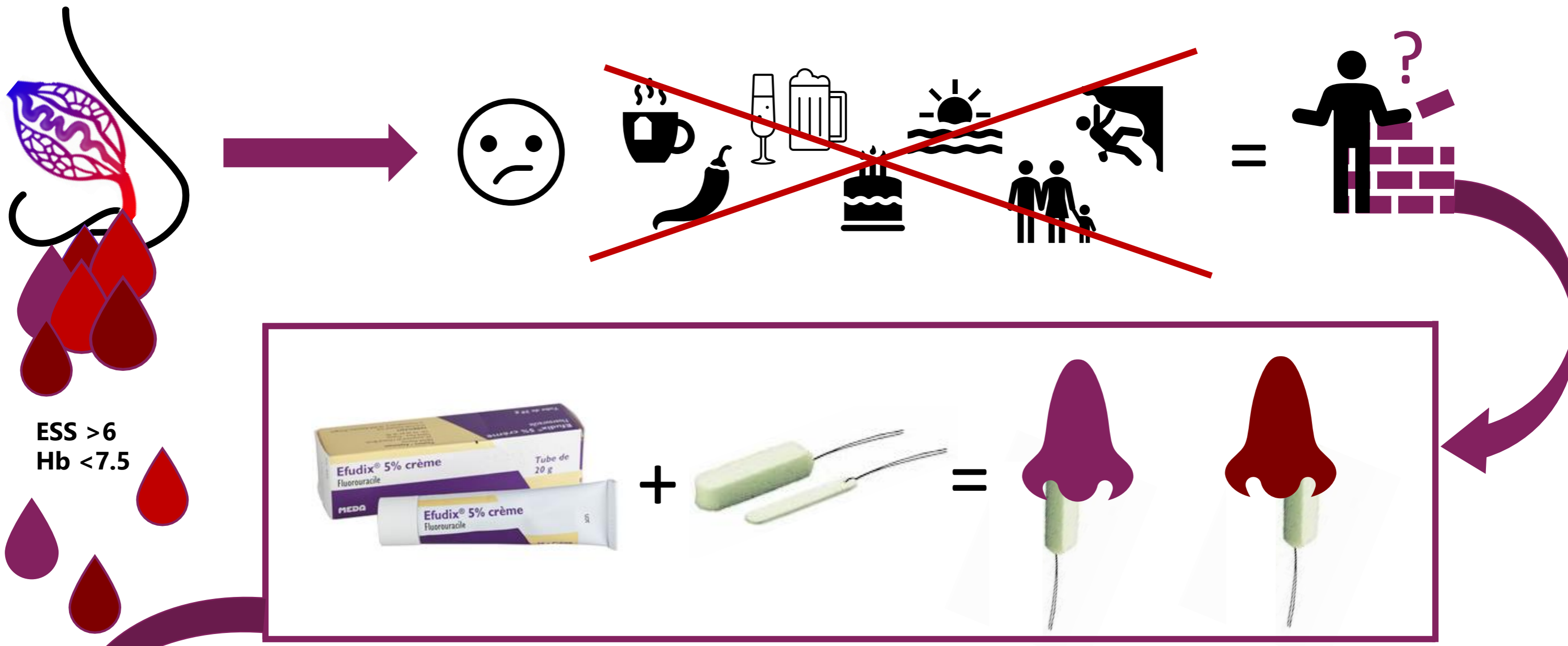


Intranasal Efudix reduces epistaxis in hereditary hemorrhagic telangiectasia

D.V.C. de Jel^{a*}, F.J.M. Disch^a, S. Kroon^b, J.J. Mager^b, F.J. Verdam^a

Department of Otorhinolaryngology^a and Pulmonology^b, Sint Antonius Hospital Nieuwegein, The Netherlands

*Drs. Dominique de Jel, dominiquedejel@gmail.com



Mean Hb pre 6.0 -> 6.8 one month post

